Focal laser Ablation Localized Prostate Cancer

Stefano Regusci Martina Martins Favre

UROAD CONCEPT

SIPC | SWISS INTERNATIONAL PROSTATE CENTER

SIPC

- Multidisciplinary group
- Prostate cancer management
- From AS to Radical Prostatectomy
- mpMRI and Biopsy (fusion, TP, in-bore…)
- Multi-Source Focal Therapy equipment
- Robotic surgical Techniques

Uroradconcept

- Prostate Cancer second opinion (patient/Prof)
- Perform Precise Dx and help ttt decision
- Help local team or relocate our
- Develop Prostate Cancer center (Dx/ttt)

Focal Therapy

Focal Therapy

Review – Prostate Cancer

The Role of Focal Therapy in the Management of Localised Prostate Cancer: A Systematic Review

Massimo Valerio [a,b,c,†,], Hashim U. Ahmed [a,b,†], Mark Emberton [a,b], Nathan Lawrentschuk [d], Massimo Lazzeri [e], Rodolfo Montironi [f], Paul L. Nguyen [g], John Trachtenberg [h], Thomas J. Polascik [i]*

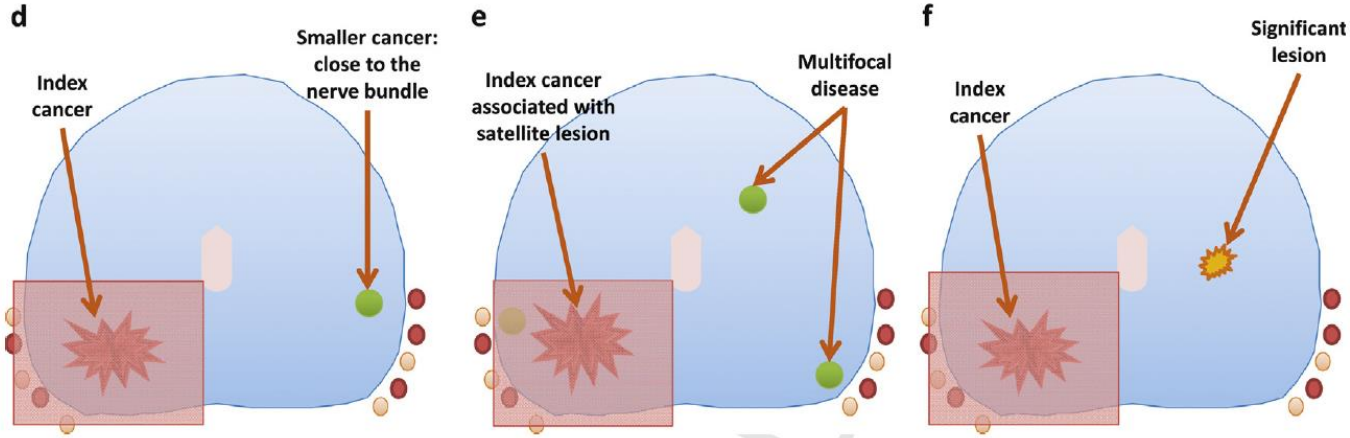

Index Lesion

Prostate Cancer and Prostatic Diseases (2010), 1–7

1365-7852/10
www.nature.com/pcan

ORIGINAL ARTICLE

Histological characteristics of the index lesion in whole-mount radical prostatectomy specimens: implications for focal therapy

M Karavitakis[1,2], M Winkler[3], P Abel[1], N Livni[4], I Beckley[3] and HU Ahmed[5]

[1]*Division of Surgery, Oncology, Reproductive Biology and Anaesthetics, Imperial College, London, UK;* [2]*Department of Urology, 'St Panteleimon' General Hospital of Nikaia, Piraeus, Greece;* [3]*Department of Urology, Imperial College Healthcare NHS Trust, Charing Cross Hospital, London, UK;* [4]*Department of Histopathology, Imperial College Healthcare NHS Trust, Charing Cross Hospital, London, UK and* [5]*Department of Urology, University College London, London, UK*

Tumor type	Total	Gleason ≥7	Gleason ≤6	Volume ≥0.5 cc	ECE	SVI
Unifocal	22	31.8	68.2	81.8	22.7	31.9
Index	78	30.7	69.3	84.6	16.6	6.4
Secondary lesions	170	0.6	99.4	12.9	1.1	0

Index Lesion

Prostate Cancer

Magnetic Resonance Imaging–Transectal Ultrasound Image-fusion Biopsies Accurately Characterize the Index Tumor: Correlation with Step-sectioned Radical Prostatectomy Specimens in 135 Patients

Eduard Baco [a,b,†,], Osamu Ukimura [b,†], Erik Rud [c], Ljiljana Vlatkovic [d], Aud Svindland [d], Manju Aron [e], Suzanne Palmer [f], Toru Matsugasumi [b], Arnaud Marien [b,g], Jean-Christophe Bernhard [b,h], John C. Rewcastle [b], Heidi B. Eggesbø [i], Inderbir S. Gill [b]*

Index Lesion correct Identification by RMN
in **95%** patients

The 3 pillars of Focal Therapy

- **Target Identification (imaging)**

(Precise Correlation between Biopsy and mpMRI)

- Treatment

- Control

MRI

LA TP



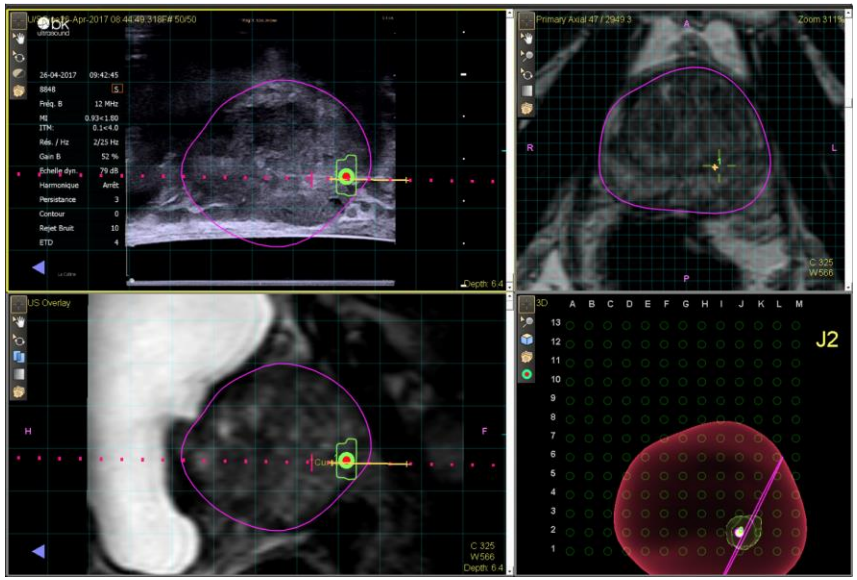

Cartography

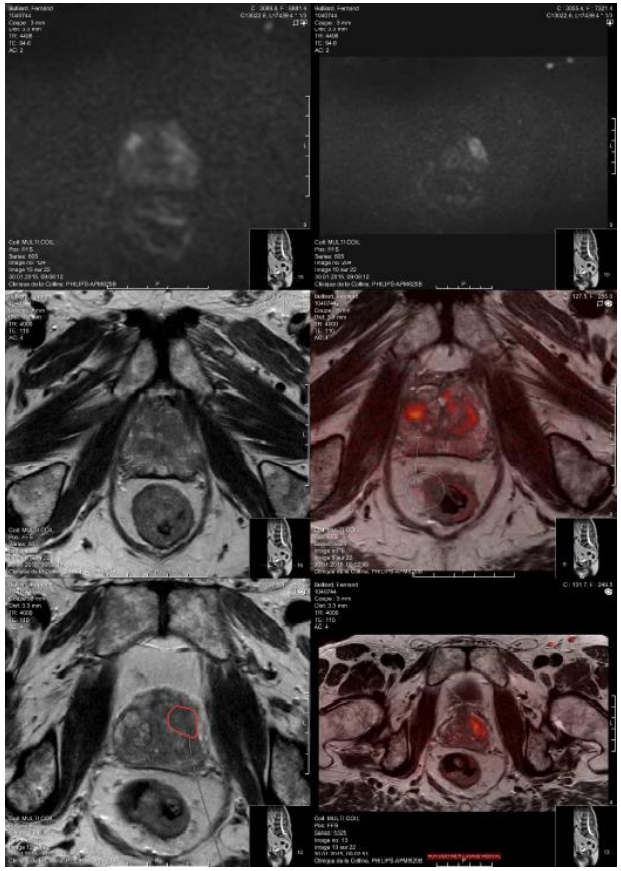

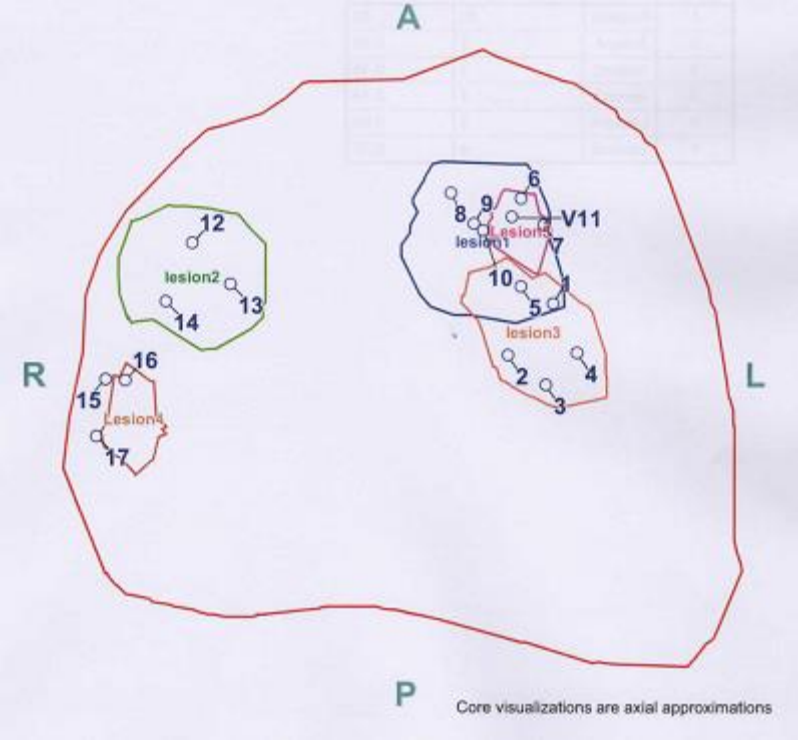

Correlation

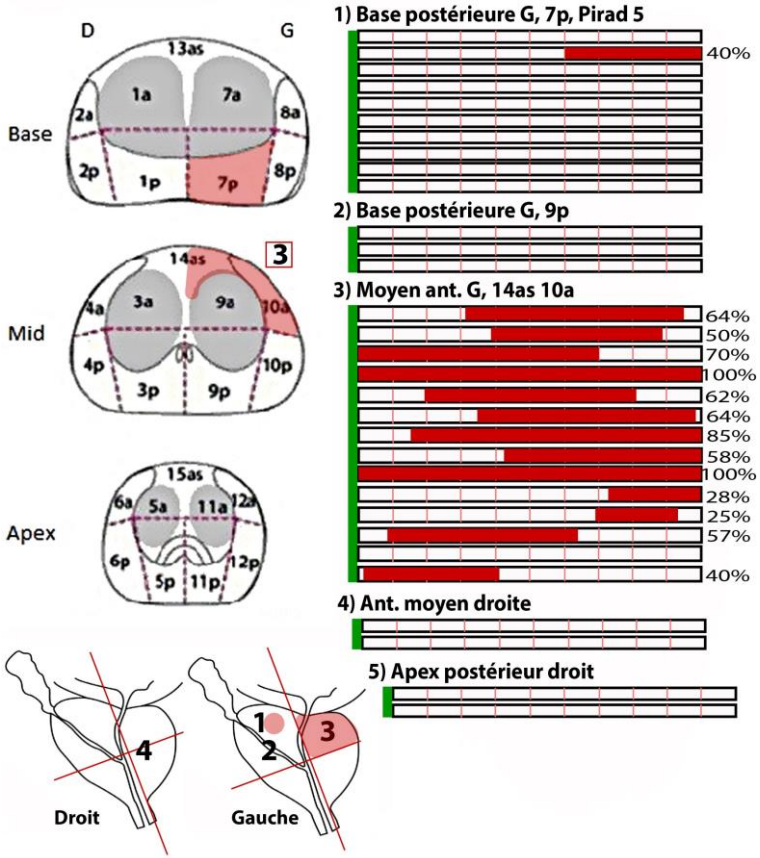

Fusion Focal Therapy

Laser (SoracteLite)
Elesta

Uronav Philips

Target

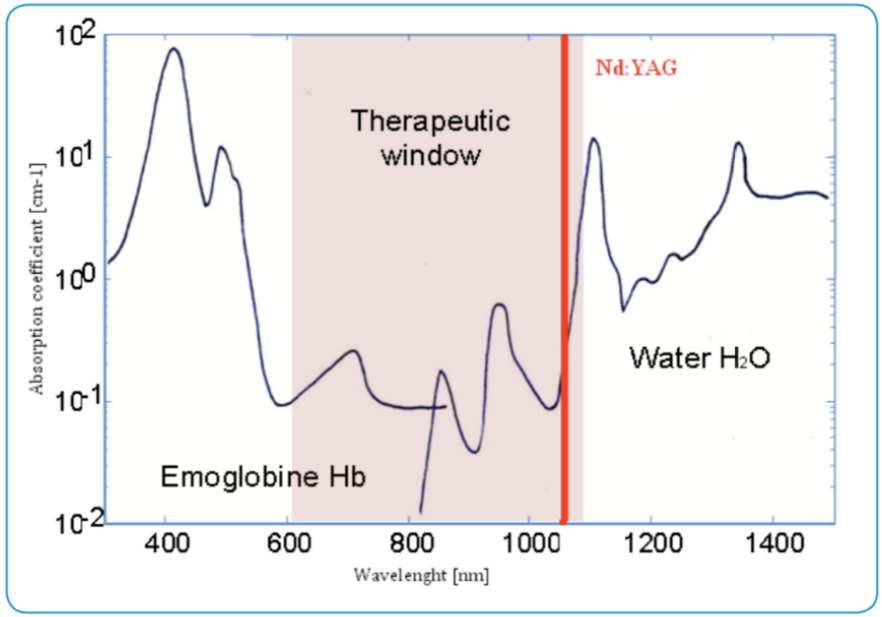

- The "Therapeutic window" is the wavelength range (λ), where light has good penetration into the tissues.
- In the therapeutic window, tissues show a low radiation absorption and consequently excellent light penetration.
- The therapeutic window is limited at a lower wavelength due to haemoglobin absorption (oxygenated HbO2 and not oxygenated Hb) and at a upper wavelength due to water absorption.

1064 nm **Nd:YAG** has an excellent tissue interaction, with low radiation absorption and high light penetration.

Laser

Laser-tissue interactions

thermal damage evaluation (area/volume) related to output-power and heat dose

("ex vivo" Porcine liver at 20°C temperature – Laser Nd:YAG – single source; plane-cut fiber)

Joules	power 4W	power 5W	power 6W
energy 600	 area 0.7 cm^2 volume 0,3 cm^3	 area 1.3 cm^2 Volume 0.7 cm^3	 area: 1.4 cm^2 volume 0.8
energy 1200	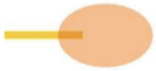 area: 1.2 cm^2 volume 0.8 cm^3	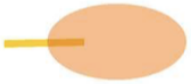 area 2.1 cm^2 volume 1.6 cm^3	 area 2.4 cm^2 volume 2.1
energy 1800	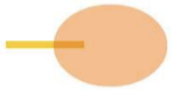 area 2.0 cm^2 volume 1.8 cm^3	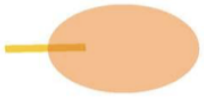 area 2.6 cm^2 Volume 2.4 cm^3	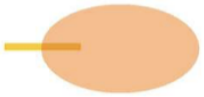 area 27 cm^2 volume 2.5
energy 2400	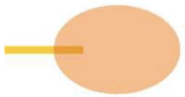 area 2.2 cm^2 Volume 2 cm^3	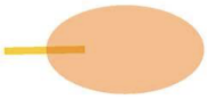 area 2.7 cm^2 Volume: 2.6 cm^3	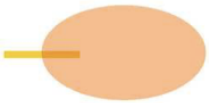 area 3.0 cm^2 volume 3.0

Planning

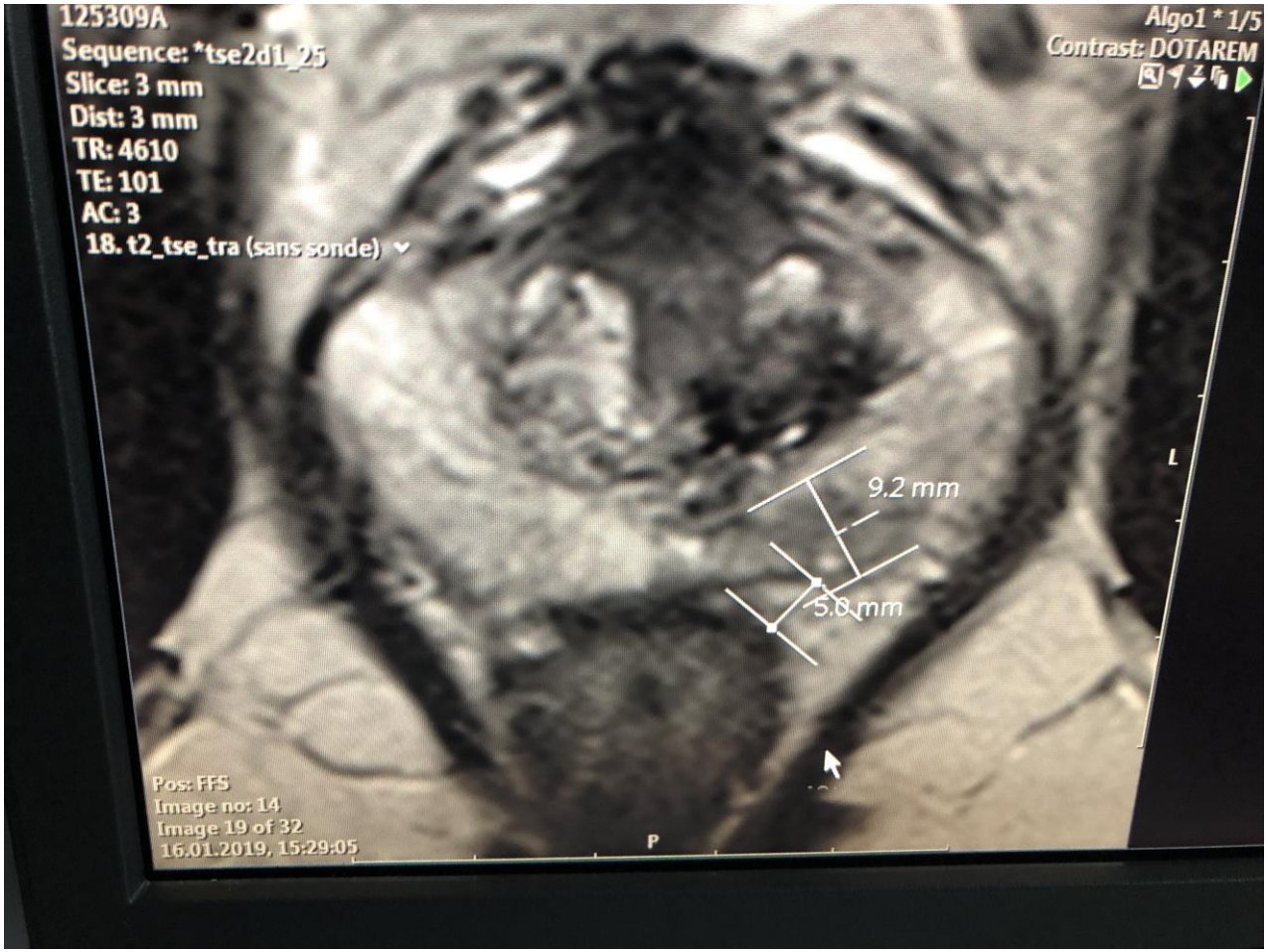
125309A
Sequence: *tse2d1_25
Slice: 3 mm
Dist: 3 mm
TR: 4610
TE: 101
AC: 3
18. t2_tse_tra (sans sonde)
Algo1 * 1/5
Contrast: DOTAREM
9.2 mm
5.0 mm
L
P
Pos: FFS
Image no: 14
Image 19 of 32
16.01.2019, 15:29:05

Planning

MRI/US Fusion

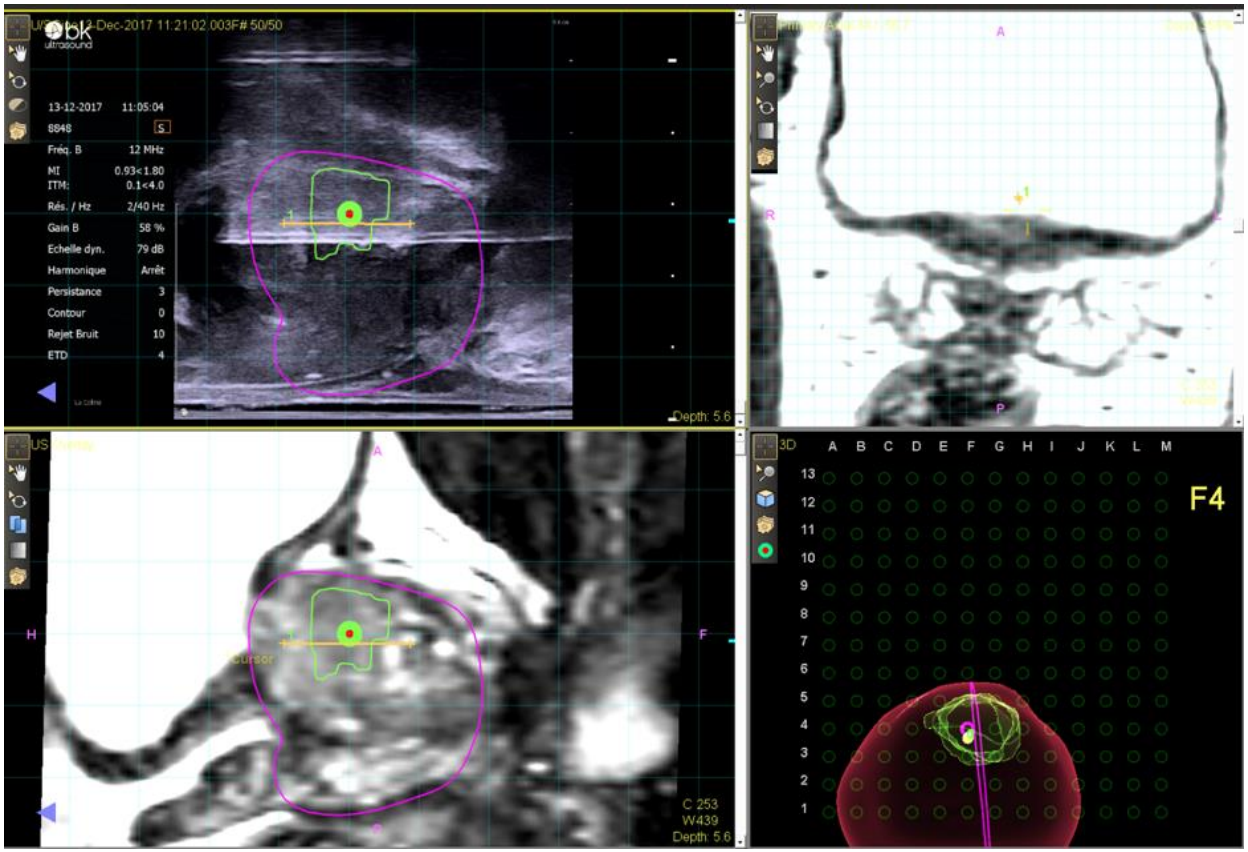

Procedure

Procedure

Procedure

Procedure


Lect. Ciné
Arrêt
Rés. / Hz
2/40 Hz
Fréq. B
12 MHz
Gain B
67 %
Dist 1 12.0 mm
Dist 2 13.3 mm
Dist 3 6.38 mm
IM: 1.08<1.80
ITM: 0.1<4.0

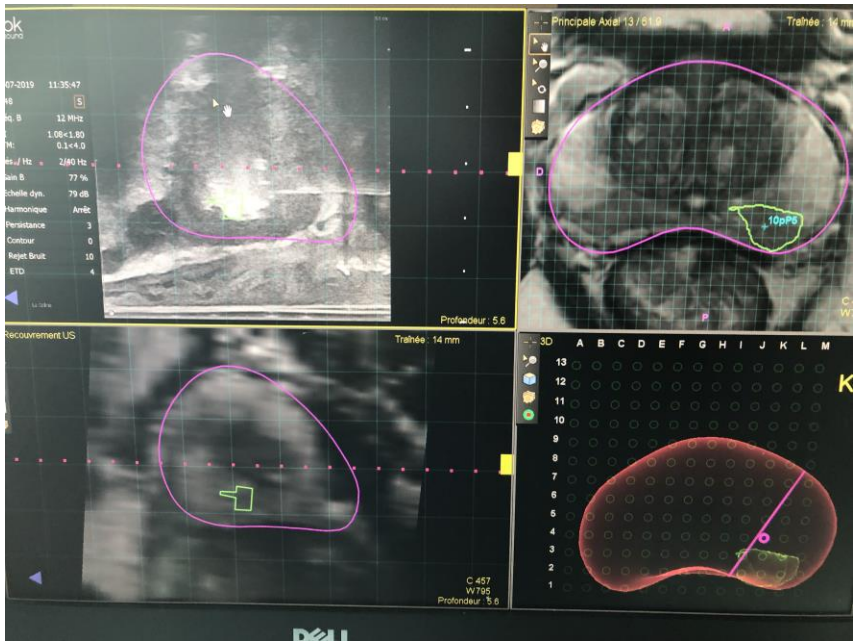
Principale Axial 13 / 61.9
Trahée : 14 mm
10pPS
Profondeur : 5.6
Recouvrement US
Trahée : 14 mm
C 457
W 795
Profondeur : 5.6
3D
A B C D E F G H I J K L M
13 12 11 10 9 8 7 6 5 4 3 2 1

Procedure

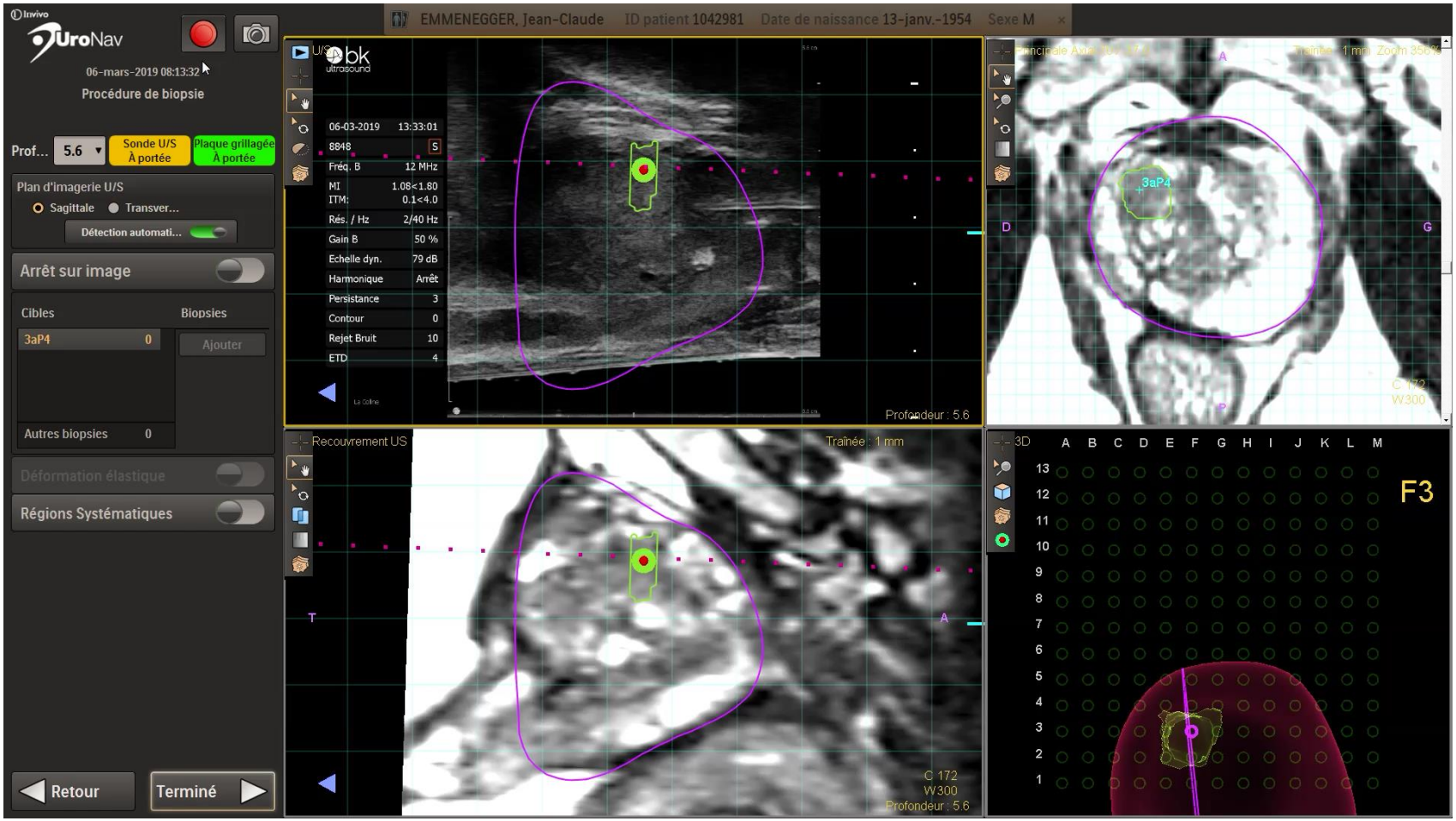
Invivo
UroNav
06-mars-2019 08:13:32
Procédure de biopsie
Prof... 5.6
Sonde U/S À portée
Plaque grillagée À portée
Plan d'imagerie U/S
Sagittale
Transver...
Détection automati...
Arrêt sur image
Cibles
Biopsies
3aP4 0
Ajouter
Autres biopsies 0
Déformation élastique
Régions Systématiques
Retour
Terminé
EMMENEGGER, Jean-Claude
ID patient 1042981
Date de naissance 13-janv.-1954
Sexe M
06-03-2019 13:33:01
8848
Fréq. B 12 MHz
MI 1.08<1.80
ITM: 0.1<4.0
Rés. / Hz 2/40 Hz
Gain B 50 %
Echelle dyn. 79 dB
Harmonique Arrêt
Persistance 3
Contour 0
Rejet Bruit 10
ETD 4
Profondeur : 5.6
3aP4
D
G
Recouvrement US
Traînée : 1 mm
T
A
C 172
W300
Profondeur : 5.6
3D
A B C D E F G H I J K L M
13 12 11 10 9 8 7 6 5 4 3 2 1
F3

Procedure

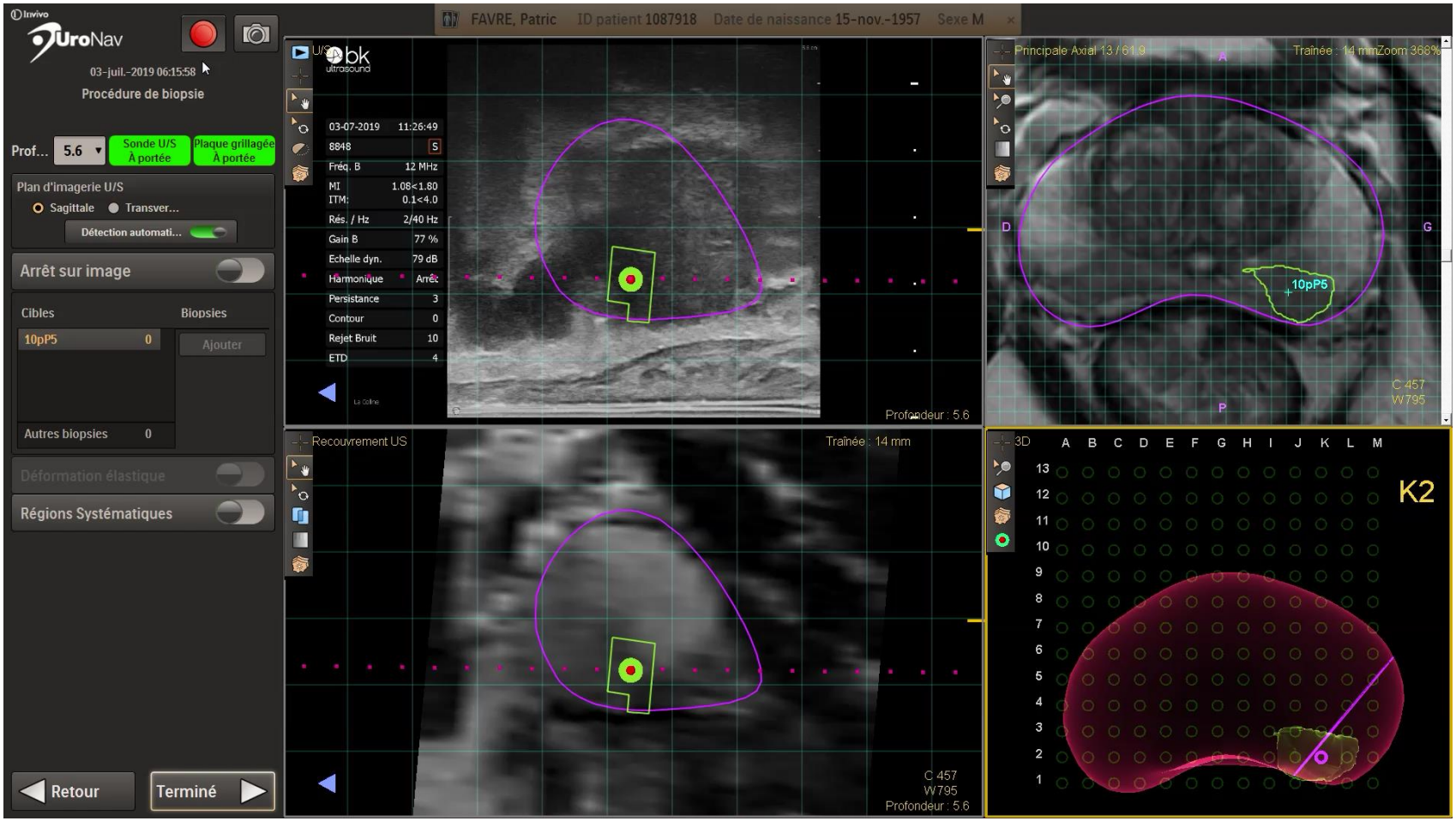
Invivo
UroNav
03-juil.-2019 06:15:58
Procédure de biopsie
Prof... 5.6
Sonde U/S À portée
Plaque grillagée À portée
Plan d'imagerie U/S
Sagittale
Transver...
Détection automati...
Arrêt sur image
Cibles
Biopsies
10pP5 0
Ajouter
Autres biopsies 0
Déformation élastique
Régions Systématiques
Retour
Terminé
FAVRE, Patric
ID patient 1087918
Date de naissance 15-nov.-1957
Sexe M
03-07-2019 11:26:49
8848 S
Fréq. B 12 MHz
MI 1.08<1.80
ITM: 0.1<4.0
Rés. / Hz 2/40 Hz
Gain B 77 %
Echelle dyn. 79 dB
Harmonique Arrêt
Persistance 3
Contour 0
Rejet Bruit 10
ETD 4
Profondeur : 5.6
Principale Axial 13 / 61.9
Traînée : 14 mmZoom 366%
A
D
G
P
10pP5
C 457
W795
Recouvrement US
Traînée : 14 mm
C 457
W795
Profondeur : 5.6
3D
A B C D E F G H I J K L M
13 12 11 10 9 8 7 6 5 4 3 2 1
K2

Control

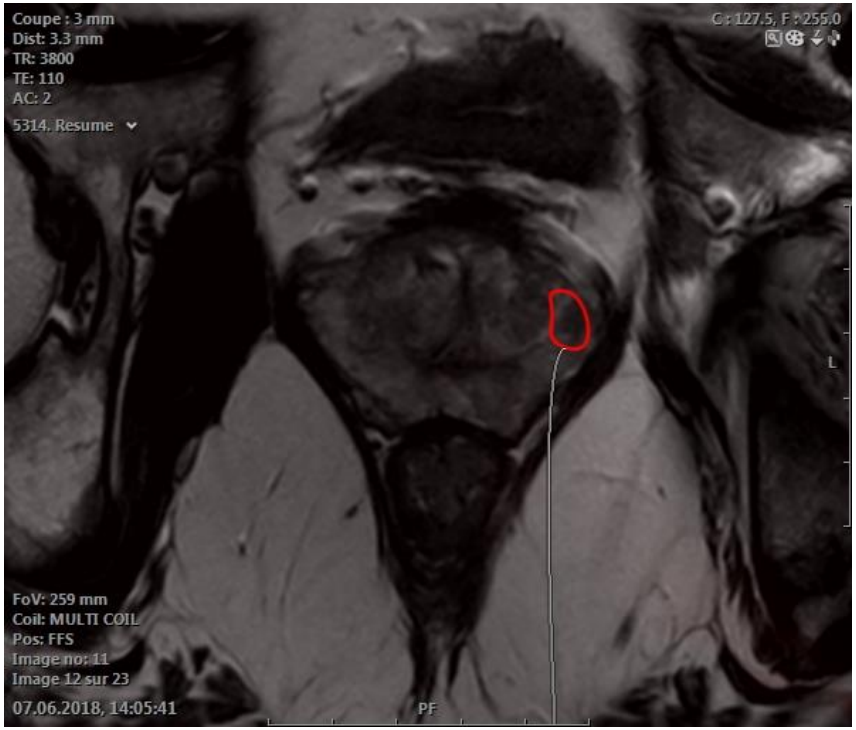
Coupe : 3 mm
Dist: 3.3 mm
TR: 3800
TE: 110
AC: 2
5314. Resume
C : 127.5, F : 255.0
L
FoV: 259 mm
Coil: MULTI COIL
Pos: FFS
Image no: 11
Image 12 sur 23
07.06.2018, 14:05:41
PF

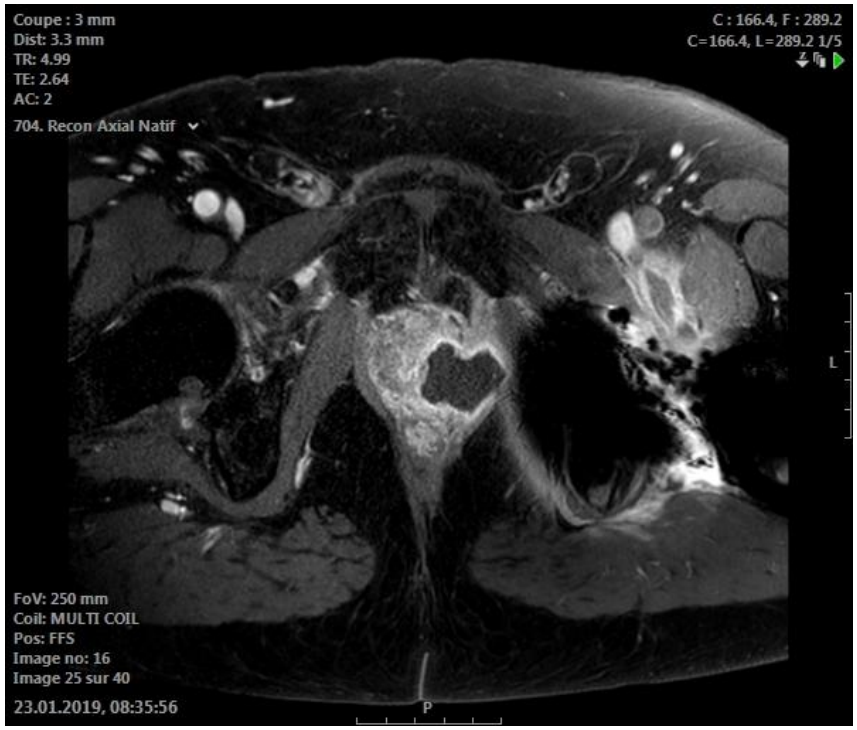
Coupe : 3 mm
Dist: 3.3 mm
TR: 4.99
TE: 2.64
AC: 2
704. Recon Axial Natif
C : 166.4, F : 289.2
C=166.4, L=289.2 1/5
L
FoV: 250 mm
Coil: MULTI COIL
Pos: FFS
Image no: 16
Image 25 sur 40
23.01.2019, 08:35:56
P

Geneva SIPC protocol

Months	1w	3	6	12	18	24	30	36
PSA		x	x	x	x	x	x	x
mpMRI	x			x		x		
Targeted biopsy (treated area)				x		X(if susp. orTP clin/PSA)		
Standard biopsy (untreated area)				x				
PROMs		x	x	x	x	x	x	x

PROMs used: IPSS, IIEF-5, EORTC QLQ-C30 and QLQ-PR25

Initial Experience (2018-2019)

n=20 cases

T1-T2/ PSA max 15ng/ml

G 3+3, 3+4

unilateral

6-9mm margins

Index lesion ttt

n=4 post HIFU

n=1 post Cryottt/Rxttt

n=9 Gleason 3+3

n=11 Gleason 3+4

n=17 anterior lesions

n=8 apex lesions

Initial Experience (2018-2019)

n=3 negative Bx

n=1 positive (less 3mm

3+3)

No significant complicat.

n=3 de novo ED

No Urinary Retention

No incontinence

No IPSS score change

Registry

TOR VERGATA
UNIVERSITY OF ROME

FLA Prostate

REGISTRY FLA PROSTATE

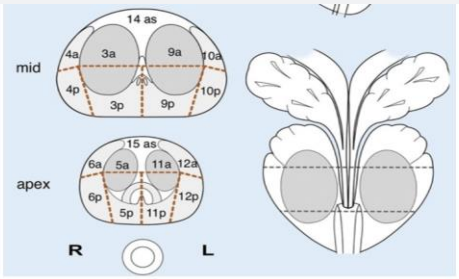

Insert Dickinson sectors according to the image above

QoL-IPSS-IIEF

QoL (Quality of Life)

0 1 2 3 4 5 6

IPSS (PC)

YES/SI NO

IIEF (PC)

REGISTRY FLA PROSTATE

Home | Staff | News and Press | References | Contacts and Access request | Documents | Registry/Registro

Scientific Director
Prof. GUGLIELMO MANENTI

Scientific Advisors
Prof. Leonardo Palombi
Dr. Stefano Regusci

Scientific P.O.C
Colleen P. Ryan, MD

STAFF

- *Dr. Tommaso Perretta*
- *Dr. Andrea Malizia*
- *Dr. Martina Martins*
- *Dr. Emanuele Caredda*
- *Prof. Nicola Toschi*
- *Dr. Andrea Duggento*

Conclusions

Efficient

Flexible (TP, MRI)

LA/GA

Repeat ttt/ Salvage

Urinary and sexual

function preservation

Long term oncological

results

Big size lesions

Need software for

planning the ttt

Focale

Table 1
A summary of the arguments for and against focal therapy in localised prostate cancer.

	Arguments Against	Arguments for
The Seven Sins		
Sin 1	• Commonly multifocal	• Sometimes unifocal • Monoclonal origin • Index lesion • Most lesions insignificant • Similar approach in other cancers
Sin 2	• Difficult to localise disease	• Template mapping biopsy • Multiparametric MRI
Sin 3	• Treats men who do not need treatment	• Overtreatment occurs with radical approaches • Half of reported cases are intermediate or high risk disease • Trials in progress exclude low risk cases
Sin 4	• Radical therapy is effective so we should accept the side effects	• Same arguments used in other cancers which are now obsolete • Men are not willing to accept any side effect unless they gain years of life in return
Sin 5	• The functional outcomes are no better than modern radical surgery	• RALP may not offer better outcomes than open prostatectomy • Erectile function poorer after RALP • Incontinence more common after RALP
Sin 6	• Focal therapy leaves cancer behind • Long term survival data is lacking	• Similar concerns in other cancers proved unfounded • Biochemical recurrence and metastatic free survival medium term outcomes are good
Sin 7	• There is no data from RCTs	• This is an issue for surgical oncology in general

Focale

- Karavitakis M, Winkler M, Abel P, et al. Histological characteristics of the index lesion in whole-mount radical prostatectomy specimens: implications for focal therapy. Prostate Cancer Prostatic Dis 2011;14(1):46–52.
- Bott SR, Ahmed HU, Hindley RG, et al. The index lesion and focal therapy: an analysis of the pathological characteristics of prostate cancer. BJU Int 2010;106(11):1607–11.
- Ahmed HU. The index lesion and the origin of prostate cancer. N Engl J Med 2009;361:1704–6.
- Eggener SE, Scardino PT, Walsh PC, et al. Predicting 15-year prostate cancer specific mortality after radical prostatectomy. J Urol 2011;185(3):869–75.
- Fütterer JJ, Briganti A, De Visschere P, et al. Can clinically significant prostate cancer be detected with multiparametric magnetic resonance imaging? a systematic review of the literature. Eur Urol 2015;68(6):1045–53.
- Villiers A, Puech P, Mouton D, et al. Dynamic contrast enhanced, pelvic phased array magnetic resonance imaging of localized prostate cancer for predicting tumor volume: correlation with radical prostatectomy findings. J Urol 2006;176(6):2432–7.
- Valerio M, Ahmed HU, Emberton M, et al. The role of focal therapy in the management of localised prostate cancer: a systematic review. Eur Urol 2014;66(4):732–51.
- Bill-Axelson A, Holmberg L, Garmo H, et al. Radical prostatectomy or watchful waiting in early prostate cancer. N Engl J Med 2013;370(10):932–42.
- Wilt TJ, Brawer MK, Jones KM, et al. Radical prostatectomy versus observation for localized prostate cancer. N Engl J Med 2012;367(3):203–13.

Focale

- Bard R, Sperling D, Futterer J. Focal laser ablation of prostate cancer: a prospective study of 59 patients. Boston: American Society of Lasers in Surgery and Medicine Annual Meeting; 2013.

- Bozzini G, Colin P, et al. Focal therapy of prostate cancer: energies and procedures. Urol Oncol. 2013;31(2): 155–67.

- Oto A, Sethi I, et al. MR imaging-guided focal laser abla- tion for prostate cancer: phase I trial. Radiology. 2013;267(3):932–40.

Focale

Table 2 – Inclusion and exclusion criteria for focal therapy trials

Inclusion criteria	
Serum PSA	PSA <15 ng/ml PSA >15 ng/ml should be counselled with caution
Clinical stage	T1c–T2a
Pathology	Gleason score 3 + 3 Gleason score 3 + 4
Life expectancy	>10 yr [35]
Prostate volume	Any; except in case of HIFU: <40 ml
Exclusion criteria	
Previous treatment: Previous treatment of the primary cancer within the prostate Previous hormone treatment for prostate cancer within 6 months before trial Previous radiation to pelvis	
Active urinary tract infection	
Radiologic imaging: PI-RADS score <3; clinically significant cancer is equivocal [26] Extracapsular extension or seminal vesicle invasion Lymph node or bone metastasis	

HIFU = high-intensity focused ultrasound; PI-RADS = Prostate Imaging Reporting and Data System; PSA = prostate-specific antigen.
These criteria are the minimal requirements for including and excluding candidates in focal therapy trials.

This presentation was presented at
EPIC Meeting on Photonics for Cancer Diagnostics and Treatment 2019

HOSTED BY

SILVER SPONSORS

EU initiatives funded by
www.photonics21.org

BRONZE SPONSORS